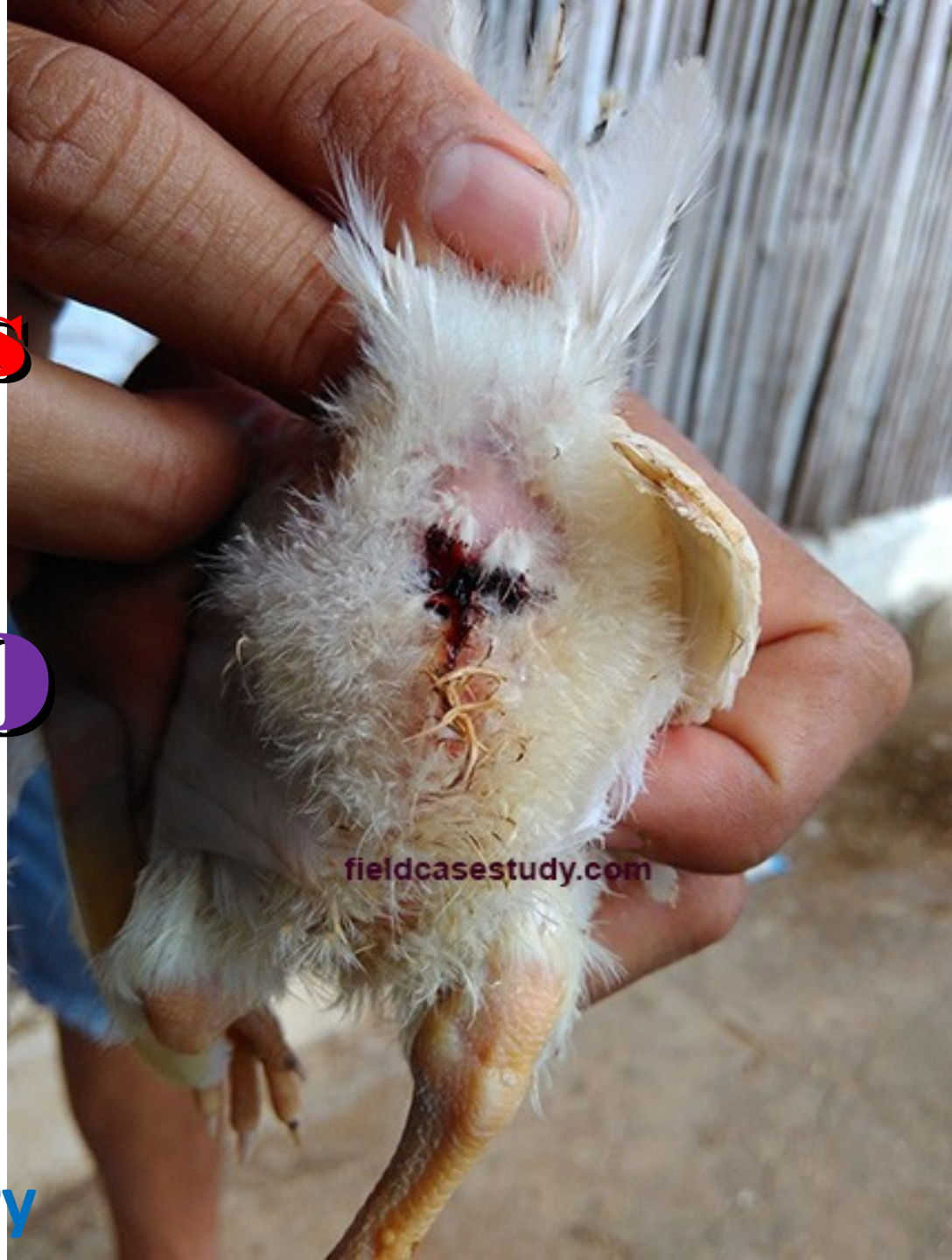

What is this?

Coccidiosis

Or

GUMBORO



fieldcasestudy.com

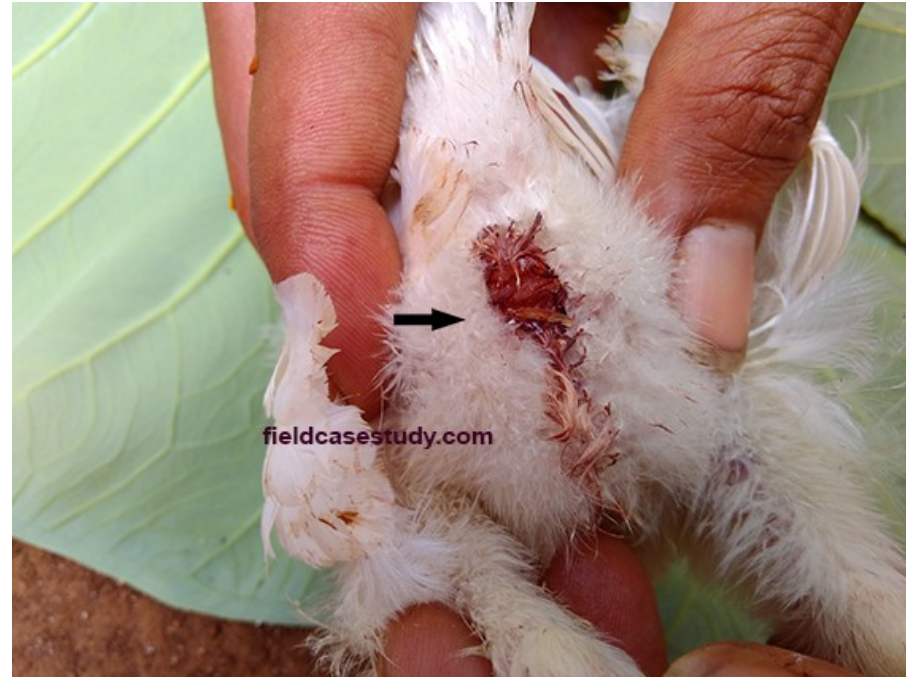Photos Galery

Which chicken suffering Coccidiosis?



A

Male chicken, 37 days old



B

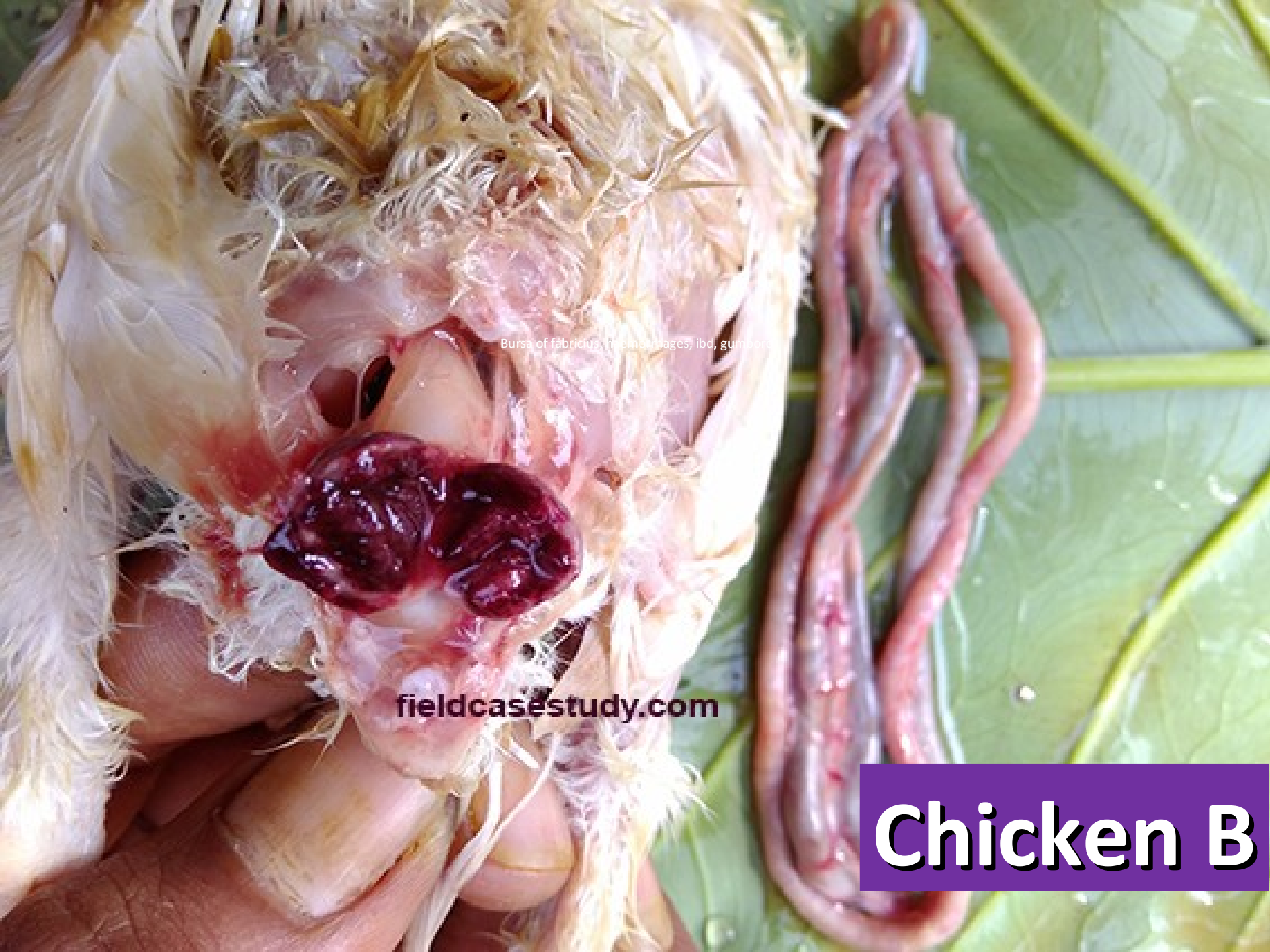Male chicken, 20 days old

Chicken B, intestine & caecum
Looks normal, there is no
haemorrhages & other severe lesion



Chicken B, intestine & caecum
Looks normal, there is no
haemorrhages & other severe lesion





Bursa of fabricius, (f, b, c, d, e, f, g, h, i, j, k, l, m, n, o, p, q, r, s, t, u, v, w, x, y, z)

fieldcasestudy.com

Chicken B

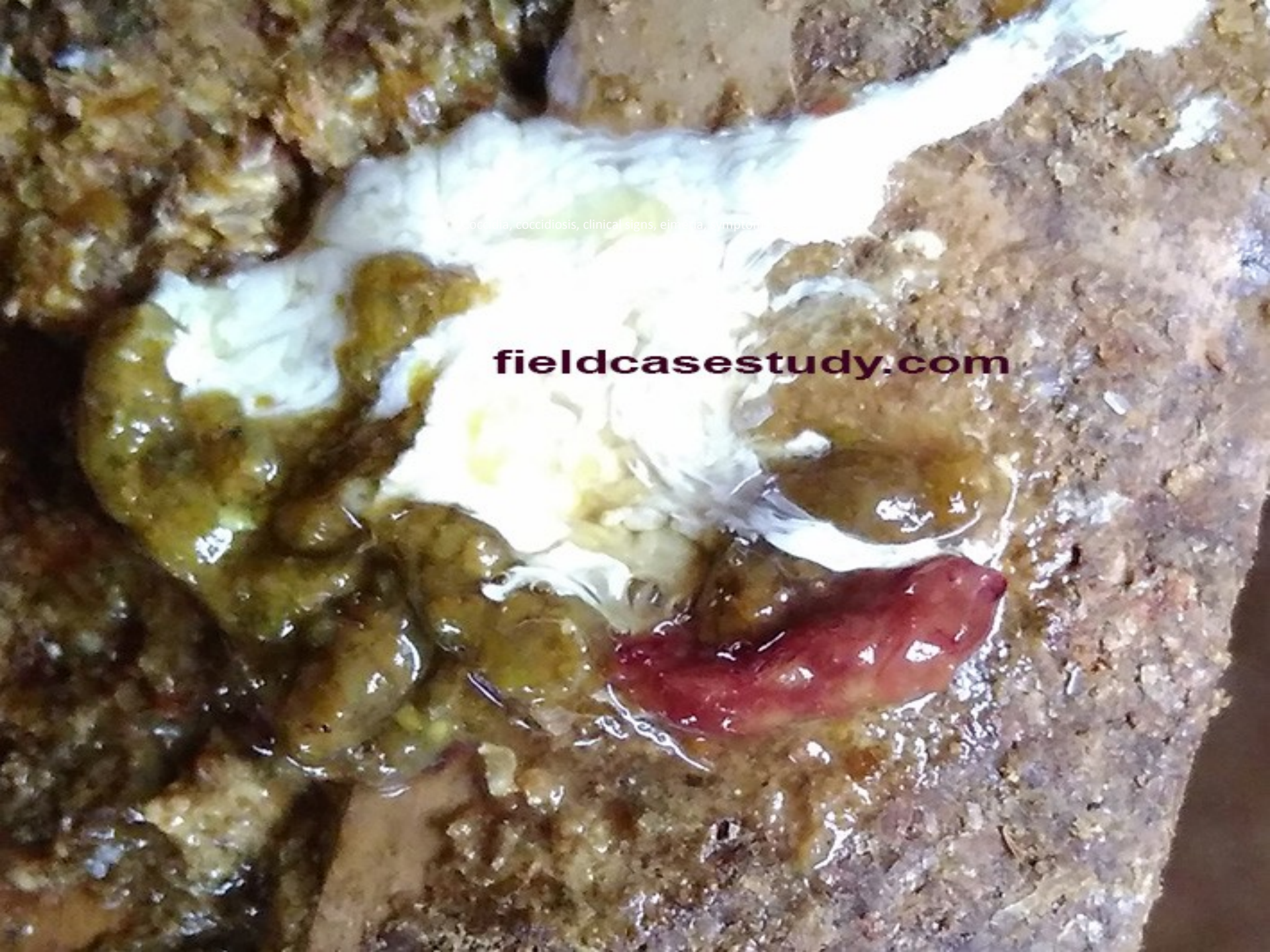Chicken B is suffering severe Gumboro



clinical symptoms, coccolossus, pos...

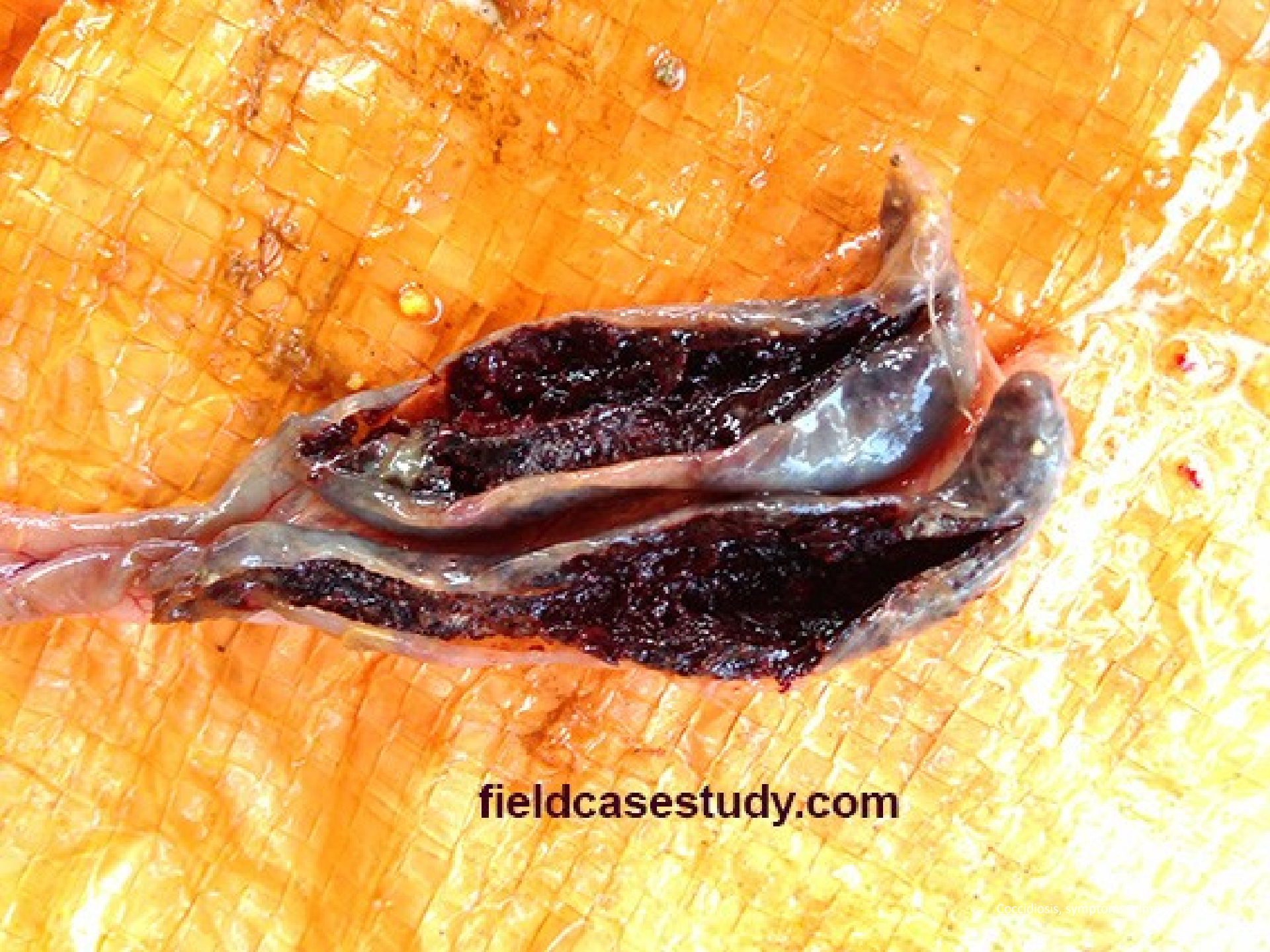fieldcasesstudy.com

Chicken A



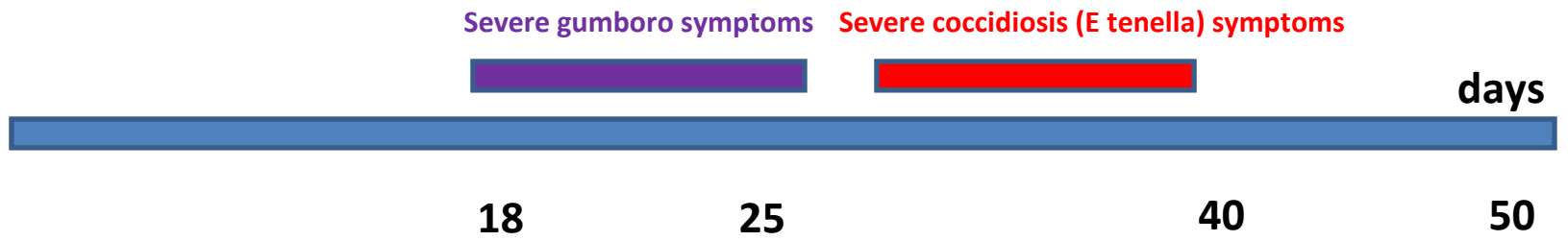
... of ... coccidiosis, clinical signs, etiology, symptoms

fieldcasestudy.com



fieldcasestudy.com

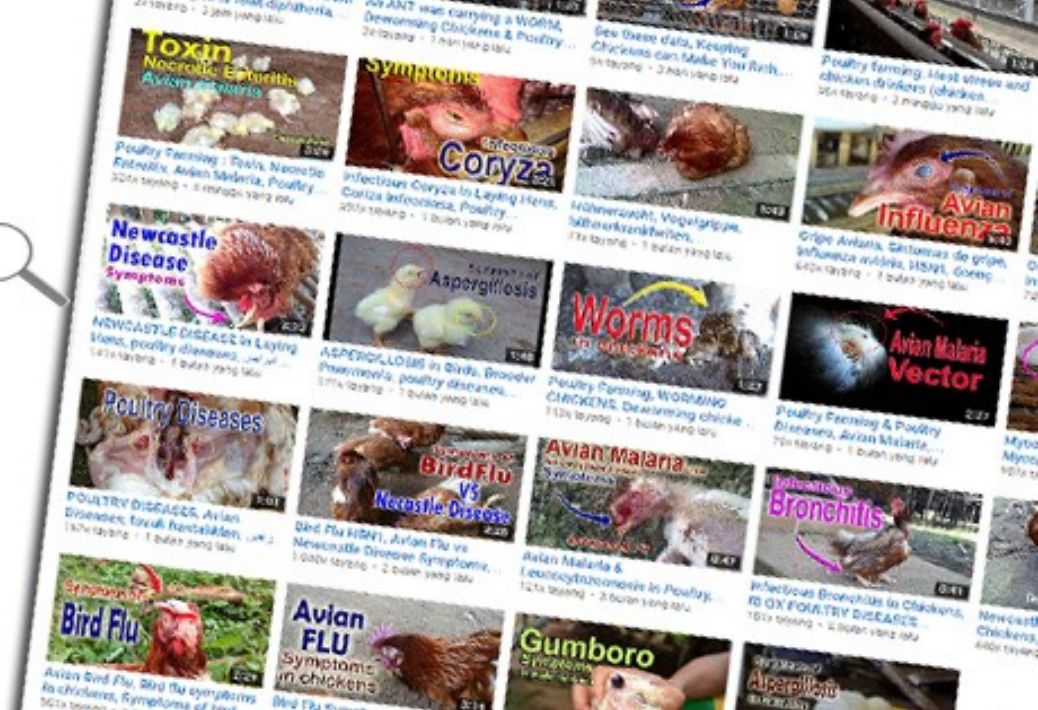
Chicken A is suffering Coccidiosis



**Visit
FieldCaseStudy.com
For
Descriptions**

Download Original Pictures here

FieldVet Channel
You **Tube**



Videos for Poultry Diseases Symptoms, Subscribe & Share