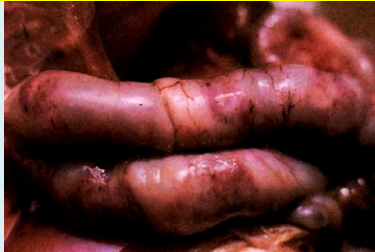
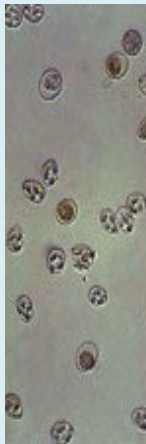
CoxyCare



INTRODUCTION

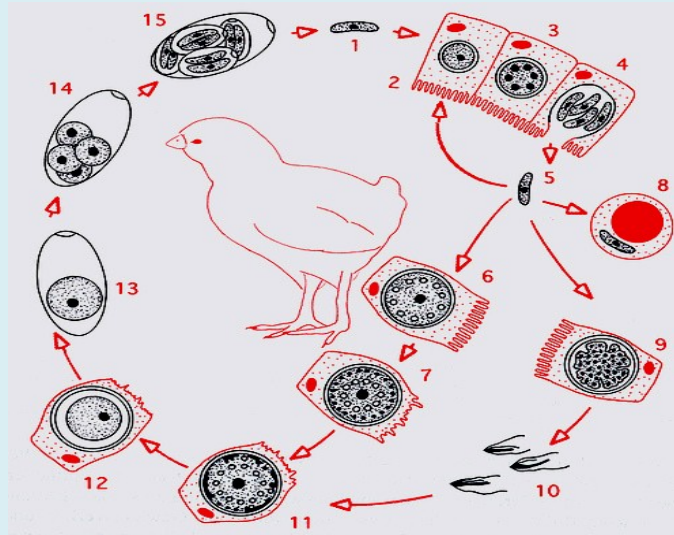


ian disease caused by infection with one or more of the many species of coccidia, which are intracellular protozoal parasites of the subphylum *Apicomplexa* and the genus *Eimeria*.

Coccidiosis is known to be caused by several different species of *Eimeria*, namely *Eimeria acervulina*, *E. maxima*, *E. tenella*, *E. necatrix*, *E. brunetti*, *E. mitis*, *E. praecox*, and possibly *E. mivati* and *E. hagai*.

Coccidiosis The species do differ in their pathogenic effect on birds, with the type of birds also playing a role. Thus, a broiler chicken will be subjected to a great deal of damage by a parasite such as *E. acervulina* because it infects large portions of the small intestine, where food digestion plays a major role.

Eimeria species grow and infect different parts of intestine with quite variable pH levels.

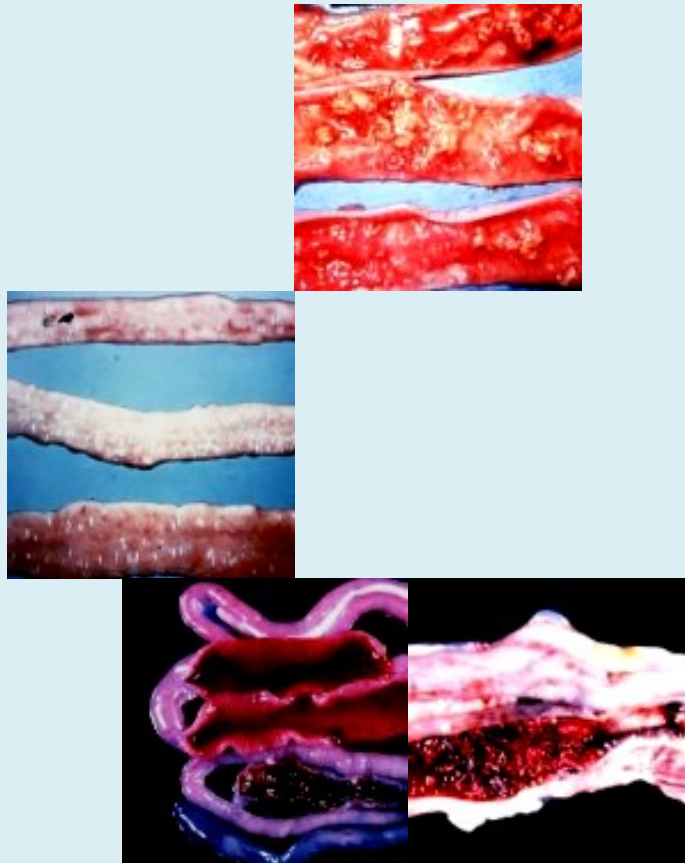


During its life cycle, the *Eimeria* parasite passes through a number of stages. The life cycle begins when the chicken ingests the infectious stage, known as the sporulating oocyst, during ground feeding or by inhalation of dust. The wall of the sporulated oocyst is ruptured by the mechanical action in the gizzard and intestinal tract, resulting in the release of four sporocysts. The sporocysts pass into the duodenum where they are exposed to bile and digestive enzymes resulting in the release of an average of two sporozoites per sporocyst.

The sporozoites are mobile and search for suitable host epithelium cells in order to penetrate and reproduce in them. Following infection of an epithelium cell, the parasite enters the schizont phase of its life cycle, producing from 8 to 16 to greater than 200 merozoites per schizont. Once released from the schizont, the merozoites are free to infect further epithelium. After from two to five of these asexual reproduction cycles, the intracellular merozoites grow into sexual forms known as the female or macrogametocyte and the male or microgametocyte. Following fertilization of the macrogametocyte by the microgametes released from the microgametocyte, a zygote is formed which creates a cyst wall about itself. The newly formed oocyst is passed out of the infected chicken with the droppings.

With the correct environmental conditions of

temperature and humidity and sufficient oxygen in the air, the oocyst will sporulate into the infectious stage, ready to infect a new host and thereby spread the disease. Thus, no intermediate host is required for transfer of the parasite from bird to bird.



E. acervulina **E. brunette** **E. necatrix**
E. tenella

The result of the Eimeria parasite infecting the digestive tract of a bird may be a reduction in weight gain, decreased feed conversion, cessation of egg production and, in some cases, death. The increase in intensive production of poultry has been accompanied by severe losses due to this parasite.

Clostridium perfringen is responsible for N.Enteritis

SIGNS

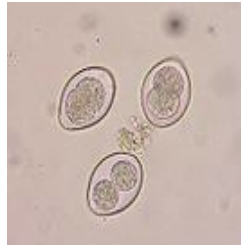Depression.
Huddling.

ruffled feathers.
Tucked appearance,
Watery diarrhoea that may occasionally be blood stained or contain clumps of mucus or shed mucosa.
Weight loss.


POST-MORTEM LESIONS

The affected area of intestine shows thickening of the wall and dilation. The contents may be haemorrhagic or be watery with white material shed from the mucosa.

DIAGNOSIS



Signs, lesions, microscopic exam of scrapings (oocysts, gamonts). Differentiate from necrotic enteritis.



Species	Location	Pathogenicity	Lesion Appearance
<i>E. adeneides</i>	Ceca and Rectum	High	Watery to solid white caseous cecal contents
<i>E. dispersa</i>	Small Intestine, primarily mid-gut, cecal neck can occur	Low	No discrete lesions, serosal surface may appear cream-colored
<i>E. gallopavina</i>	Yolk-sac to rectum	High	White or Pink ulcerations of ileal and(or) rectal mucosa. White caseous material may be found in the lower intestine and (or) ceca.
<i>E. innocua</i>	Anterior half of small intestine	None	None
<i>E. meleagridis</i>	Yolk-sac to rectum and maybe ceca	None	Cream colored serosal surface. Potential petechial hemorrhages in posterior small intestine
<i>E. meleagrimitis</i>	Middle intestine but may migrate throughout the small intestine	High	Thickened jejunum containing colorless to pink fluid. The remainder of the small intestine may be congested with petechial hemorrhages on mucosal surface
<i>E. subrotunda</i>	Anterior half of the small intestine	None	None

Eimeria spp. that are Turkey specific

PRESENT METHODS OF TREATMENT AND PREVENTION

**Contemporary anticoccidial products
and recommended doses for prophylactic treatment of coccidiosis in chickens
(Modified from Conway and McKenzie 2007).**

Chemical name	Poultry category	Concentration in feed (ppm)
Amprolium	Broiler, rearing	125–250
	Broiler, rearing	
Amprolium + ethopabate		125–250 + 4
Aprinocid	Broiler	60
	Broiler, rearing	125
Clopidol	Broiler	30
Decoquate	Broiler, rearing	1
Diclazuril	Broiler, rearing	125
Dinitolmide (zoalene)	Broiler, rearing	3
Halofuginone	Broiler, rearing	20
Nequinate (methyl benzoquate)		

**Contemporary anticoccidial products
and recommended doses for prophylactic treatment of coccidiosis in chickens
(Modified from Conway and McKenzie 2007).**

Chemical name	Poultry category	Concentration in feed (ppm)
Nicarbazin	Broiler	125
	Broiler	33
Robenidine	Broiler	75–125
	Broiler	5–6
Polyether ionophores	Broiler	5–6
	Broiler	5–6
Lasalocid	Broiler	5–6
	Broiler	5–6
Maduramicin	Broiler	5–6
	Broiler	5–6

Several attempts have been made to control Coccidiosis. Prior to the advent of chemotherapeutic agents, improved sanitation using disinfectants, together with mechanical removal of litter, were the main methods employed. In addition, the introduction of coccidiostatic agents in the feed or drinking water, along with good management practices, has resulted in some success at disease control. However, such agents have been found to suffer from a drop in effectiveness over the years, due partly to the development of drug resistant strains of coccidia. Furthermore, several chemotherapeutic agents have been found to leave residues in the meat of commercial birds, thereby often making it unsuitable for consumption.

It is known that Robenidine hydrochloride can be utilised in the treatment of warm blooded animals, in particular, fowl, infected with the protozoal disease Coccidiosis.

Cocci oocysts are very resistant to most disinfectants except formaline spray.

Other attempts to control the disease have been made immunologically. These have included the

development of live vaccines and the use of genetic engineering to formulate vaccines. Many of these efforts have focused on the use of *Eimeria* proteins as the active component of the vaccine.

However vaccines against Coccidiosis are not safe, ineffective, not easy to administer and of high cost.

Limiting factor of the use of vaccines against coccidia is due to the inclusion of several species of *Eimeria* in one vaccine; which results in further decrease in average body weight gain, Feed Conversion Ratio.

Ionophores are incompatible with some therapeutic antibiotics like tiamulin, chloramphenicol, erythromycin, oleandomycin and certain sulphonamides. Ionophores are also incompatible with some antioxidants (XAX-M, Duokvin, TD; Umemura et al. 1984; Prohaszka et al. 1987; Dowling 1992; Von Wendt et al. 1997).

The worldwide intensive use of anticoccidial drugs to prevent coccidiosis has inevitably led to the development of resistance to all anticoccidial drugs as long-term exposure to any drug will result in loss of sensitivity. The widespread occurrence of resistance has been described in the United States of America, South America, Europe and China (Jeffers 1974a, 1974b, 1989; Chapman 1978, 1982, 1984, 1997; Ryley 1980; Hamet 1986; Litjens 1986; McDougald et al. 1986, 1987; Zeng and Hu 1996; Zhou et al. 2000; Peek and Landman 2003; Peek and Landman 2004).

In some cases resistance is induced very quickly, as in the case of quinolones and pyridinols, which led to a decline in their use, while in other instances it may take several years as in the case of the ionophores.

Coban, Avatec, allow leakage of oocysts, so the birds can build up an immunity to the parasite. Also, the birds can ingest more coccidia oocysts from the litter.

Amprolium, sulfadimethoxine, and sulfaquinoxaline are effective against coccidia as a treatment,

however toxicity and withdrawal times are a matter of concern with sulfa-drugs.

ECONOMICS:

In India, the only vaccine, i.e. Livacox Q, a live attenuated vaccine containing *Eimeria tenella*, *E.acervulina*, *E. maxima* and *E. necatrix* species is used in some of the breeder farms. Coccidia vaccination is not a common practice for commercial layers. Cost of each dose is Rs 4.00.

In a rough estimate, it was assumed that 5 per cent of the flock reared was inflicted to some degree at about 3rd week of age. A standard chemotherapy considered was a combination of amprolium and sulphaquinoxaline @ 1g/L of drinking water for 2 days, then 2 days gap and repeat of same drug @ 0.5 g/L for next 2 days.

A comparison of loss (in Rs) between type of birds and in-between economic parameters due to coccidiosis in India for the year 2003-04

Economic parameters	Type of birds				Total
	Commercial broiler	Commercial layer	Broiler breeder	Layer breeder	
Chemoprophylaxis	30819262	22515000	1146300	150150	
54630712	4.80				
Chemotherapy	14589000	4503000	229260	30030	
19351290	1.70				
Mortality	9563900	105445	26384	5258	
9700987	0.85				
Vaccination	-	-	3821000	500500	
4321500	0.38				
Reduced body wt gain	775648500	-	-	-	
775648500	68.08				
Increased FCR	258549500	-	-	-	
258549500	22.70				
Egg production loss	-	13133750	3438900	450450	
17023100	1.49				
Total	1089170162	40257195	8661844	1136388	Grand
Total					11392
Percentage	95.61	3.53	0.76	25589 0.10	

(A.K. Beraa, D. Bhattacharyaa, D. Pana, A. Dharab, S. Kumarc and S.K. Dasa; Evaluation of Economic Losses due to Coccidiosis in Poultry Industry in India; Agricultural Economics Research Review Vol. 23 January-June 2010 pp 91-96)

REVIEW OF LITERATURE:

Comparative study of effect of herbal and traditional coccidiostats was conducted in broilers challenged with coccidial infection (field isolate *Eimeria tenella*). The coccidiostats used were herbal and traditional drug. The results revealed significantly ($P < 0.05$) higher weights in herbal coccidiostat supplemented group than the group

fed with traditional coccidiostat (Salinomycin) at the end of experiment (35 days). Significant ($P < 0.05$) improvement in feed conversion ratio (FCR) was recorded in groups added with herbal coccidiostats while no difference was found in birds fed with traditional coccidiostats when compared with control. The highest mortality (6%) was observed in control group followed by group fed with traditional coccidiostat (4%) and no mortality in groups treated with herbal coccidiostats. (Jadhav N.V., Thimmareddy. P. M., Naik.D.T., Waghmare P.G., Honnappagol S.S; Comparative efficacy of herbal and traditional coccidiostats on performance of broilers challenged with coccidial infection; Indian Journal of Poultry Science Year : 2008, Volume: 43, Issue: 3)

Results showed that oral administration of crude garlic ameliorated the adverse impacts of hepatic coccidiosis on rabbits when used as a prophylactic, but garlic was less effective as a therapeutic.

(<http://www.ncbi.nlm.nih.gov/pubmed/20473715>)

[Improved resistance to Eimeria acervulina infection in chickens due to dietary supplementation with garlic metabolites.](#)

The effects of a compound including the secondary metabolites of garlic, propyl thiosulphinate (PTS) and propyl thiosulphinate oxide (PTSO), on the in vitro and in vivo parameters of chicken gut immunity during experimental Eimeria acervulina infection were evaluated. In in vitro assays, the compound comprised of PTSO (67 %) and PTS (33 %) dose-dependently killed invasive E. acervulina sporozoites and stimulated higher spleen cell proliferation. Broiler chickens continuously fed from hatch with PTSO/PTS compound-supplemented diet and orally challenged with live E. acervulina oocysts had increased body weight gain, decreased faecal oocyst excretion and greater E. acervulina profilin antibody responses, compared with chickens fed a non-supplemented diet. Differential gene expression by microarray hybridisation identified 1227 transcripts whose levels were significantly altered in the intestinal lymphocytes of PTSO/PTS-fed birds compared with non-supplemented controls (552 up-regulated, 675 down-regulated). Biological pathway analysis identified the altered transcripts as belonging to the categories 'Disease and Disorder' and 'Physiological System Development and Function'. In the former category, the most significant function identified was 'Inflammatory Response', while the most significant function in the latter category was 'Cardiovascular System Development and

Function'. This new information documents the immunologic and genomic changes that occur in chickens following PTSO/PTS dietary supplementation, which are relevant to protective immunity during avian coccidiosis. PMID:22717023

(<http://worldwidescience.org/topicpages/x/x-irradiated+eimeria+acervulina.html>)

Effect of Dietary Inclusion of Probiotic, Prebiotic and Butyric Acid Glycerides on Resistance against Coccidiosis in Broiler Chickens

This research was conducted to investigate the effects of single or combined use of probiotic (Primalac), prebiotic (Fermacto) and butyric acid glycerides (Baby C4) compared to salinomycin on resistance against coccidiosis in broiler chickens challenged with *Eimeria*. One day-old male Ross 308 broiler chicks were divided into 9 cages with 15 birds per each. Birds of different treatments received a regular corn-soybean meal basal diet supplemented with feed additives; none of them in negative control (C-), salinomycin in positive control (C+), probiotic in PRO group, prebiotic in PRE group, butyric acid glycerides in BAG group, probiotic + prebiotic in PRO+PRE group, probiotic + butyric acid glycerides in PRO+BAG group, prebiotic + butyric acid glycerides in PRE+BAG group, and probiotic + prebiotic + butyric acid glycerides in PRO+PRE+BAG group. At 28 d of age, 8 birds from each treatment were removed and kept separately in other cages (2 birds/cage) to challenge with *Eimeria*. These separated chicks were orally challenged with 1×10^5 *E. acervulina* and 9×10^4 *E. tenella*. Positive effect ($P < 0.05$) was observed in the duodenal and cecal lesion scores in any of the supplemented groups when compared to that of the C-. There was no significant difference between all supplemented groups and C+ for cecal lesion score. PRO, PRE+BAG, PRO+PRE, PRO+BAG and PRO+PRE+BAG reduced ($P < 0.05$) oocyst shedding in birds challenged with *Eimeria* oocysts compared to the C-, and there was no significant difference between PRO+PRE, PRO+BAG, PRO+PRE+BAG and C+. These results demonstrate that prebiotic, butyric acid glycerides and especially probiotic or its combination with prebiotic or butyric acid glycerides enhance the resistance of birds and partially protects against coccidiosis. Therefore, it seems some of these supplements, in comparison to salinomycin, can diminish partially the adverse effects of coccidiosis.

(<http://worldwidescience.org/topicpages/x/x-irradiated+eimeria+acervulina.html>)

Coccidiosis is a common infectious disease in poultry, causing major economic losses. The aim of this study was first, to investigate the effects of synbiotic Biomin (R) IMBO on performance of broilers in normal condition (experiment 1) and secondly, to evaluate the influence of synbiotic on severity of intestinal lesion score and fecal oocyst shedding of the broilers challenged with coccidian (experiment 2). There were four dietary treatments in each experiment; basal diet (control) and basal diet +0.05, 0.1 or 0.15% synbiotic Biomid (R) IMBO of diet. In experiment 1, 400 day-old male broiler chicks were randomly assigned to 16 pens (25 birds/pen) and were fed regular non medicated broiler starter (0-10 d), grower (11-28 d) and finisher (29-42 d) diets. The measured traits were: Body weight gain (BWG), feed intake (FI) and feed conversion ratio (FCR) at the end of each period. In experiment 2, on 10 d, four birds from each pen used in experiment 1 (totally 64 birds) were transferred to battery. On 15 d, birds were inoculated esophageally with 5000 oocysts of either *Eimeria acervulina* or *Eimeria tenella*. On 6 day after postinoculation, intestinal lesion score and number of oocysts excreted for successive five days were determined. The results showed that BWG was increased significantly ($P < 0.05$) in broilers fed diet containing 0.1 and 0.15% synbiotic, when compared to control group, from 1 d to 42 d. The presence of synbiotic in diet made significant improvement ($P < 0.05$) in FCR of finisher and total experimental periods. All groups fed diets with synbiotic significantly ($P < 0.05$) shed less oocysts than non-supplementation groups. The lowest lesions score of duodenum and cecum were observed in broiler fed diet with 0.15% synbiotic. In conclusion, it can hypothesize that synbiotic Biomin (R) IMBO can promote growth and have protective properties against coccidiosis in broiler diets.

(GHASEMI H.A., SHIVAZAD M., ESMAEILNIA K., KOHRAM H., KARIMI M.A.;

THE EFFECTS OF A SYNBIOTIC CONTAINING ENTEROCOCCUS FAECIUM AND INULIN ON GROWTH PERFORMANCE AND RESISTANCE TO COCCIDIOSIS IN BROILER CHICKENS; JOURNAL OF POULTRY SCIENCE; 2010; 47(2); 149-155.)

Recently, a research group in the school of veterinary medicine at Aristotle University of Thessaloniki, Greece has evaluated the effect of dietary supplementation of feed with different probiotics preparation given to experimentally challenged broilers on day 14 with coccidian (*Eimeria tenella* sporulated oocysts). The experimental groups consisted of controls (positive and negative), a group was challenged with *E. tenella* and was given the anticoccidial lasalocid at the level of 60 mg/kg feed, and the remaining groups were all challenged with *E. tenella* and were given the basal diet supplemented with different probiotic preparations. These probiotics preparations included *Enterococcus faecium*, *Bifidobacterium animalis*, *Lactobacillus reuteri*, *Bacillus subtilis* and the multispecies probiotic mix of 5 poultry specific strains: *Enterococcus faecium*, *Pediococcus acidilactici*, *Bifidobacterium animalis*, *Lactobacillus salivarius* and *Lactobacillus reuteri* (PoultryStar®, BIOMIN GmbH, Austria). The overall performance of birds fed PoultryStar® was significantly higher than the infected control groups, while overall oocyst shedding was significantly lower in the lasalocid treated group. The latter group also showed significantly lower caecal lesion scores compared to the untreated infected group but did not differ from the *Enterococcus faecium*, *Bifidobacterium animalis* and PoultryStar® groups. These results suggest that probiotics could be used to reduce the impact of coccidiosis in broilers.

The same research group conducted another experiment to support their previous findings. They looked at the effect of PoultryStar® on the performance and gut health of broilers experimentally challenged with coccidia (*E. acervulina*, *E. maxima* and *E. tenella* sporulated oocysts). The 5 experimental groups consisted of controls (positive and negative), 2 groups challenged with mixed *Eimeria* species that were given PoultryStar® in feed, and a final group challenged with mixed *Eimeria* species that were treated with lasalocid at 75 mg/kg. The results of this study supported the previous trial and showed that PoultryStar® supplementation exerted an anticoccidial effect against *Eimeria* species, reflected on the birds' performance that was similar to lasalocid.

PoultryStar® groups showed lower numbers of oocysts shedding, lesion scores and bloody faeces than the control infected group but higher numbers than the lasalocid group. Also PoultryStar® treated groups gave the highest values of villous height and villous height to crypt depth ratios in comparison to all other groups.

(Dr Wael ABDELRAHMAN DVM MVSc PhD; Can probiotics help in coccidiosis control in your poultry flock? Poultry Line Volume 13; Issue 4; April 2013)

ARS scientists demonstrate dietary immunomodulation strategies to enhance gut innate immunity in poultry in collaboration with scientists at the Pancosma S.A., Switzerland. Their recent study found that extracts of plants (turmeric and milk thistle) and mushrooms (shiitake and reishi) stimulate poultry innate immunity and protected against avian coccidiosis. These studies represent first evidence for the immunologically-based enhancement of innate immunity in chickens by medicinal plants and mushrooms and provide new knowledge that will further the development of alternative disease control strategies to enhance animal productivity.

In vitro culture of chicken spleen lymphocytes with extracts of turmeric (*Curcuma longa*), milk thistle (*Silybum marianum*), shiitake (*Lentinus edodes*) or reishi (*Ganoderma lucidum*) mushrooms induced significantly increased cell proliferation and activated normal macrophages to produce effector molecules of innate immunity. All of the extracts also uniformly inhibited the growth of chicken tumor cells in vitro. These studies represent first evidence for the immunologically-based enhancement of innate immunity in chickens by medicinal plants and mushrooms and provide new knowledge that will further the development of alternative disease control strategies to enhance animal productivity.

(http://www.ars.usda.gov/research/publications/publications.htm?seq_no_115=242229)

CONTENTS OF COXYCARE & THEIR MODE OF ACTION

Aegle marmelos possesses astringent, digestive and stomachic properties. It has significant activity against intestinal parasites like *Ascaris lumbricoides* Linn., *Entameba histolytica* and *Giardia* spp.

Betaine

The osmoprotective effect of betaine is not restricted to the intestinal cells, but also affects the developing stages of the coccidia.

Another contributing factor to the positive effect of betaine on coccidiosis infection may be the fact that it increases intraepithelial lymphocytes in the duodenum and the functional properties of phagocytes of *Eimeria*-infected chickens (Klasing et al. [2002](#)).

Bombax ceiba gum

is credited with astringent, tonic and demulcent properties and is used in dysentery.

Cinnamomum zeylanicum

possesses aromatic, astringent, stimulant and expectorant properties. It is beneficial in gastric irritation, cramps of the stomach, diarrhea and dysentery.

Curcumin

Eimeria maxima-infected chicks fed with diets supplemented with 1% curcumin showed an improved weight gain and a reduction in the lesion scores and oocyst excretion. Nevertheless, the activity was only shown against *E. maxima* and not against *E. tenella*. A significant reduction of plasma and concentrations was only found in *E. maxima*-infected and curcumin-treated birds and provide a possible explanation for the difference in anticoccidial activity found for both *Eimeria* spp. (Allen et al. 1998). A similar effect on lesion scores, oocyst shedding, growth, and plasma and concentrations was found for γ -tocopherol. The antioxidative properties of curcumin by inhibiting NOS induction by macrophages stimulated with lipopolysaccharide and interferon- γ has been shown previously (Brouet and Ohshima 1995). Although NO is an important defence mechanism against the invasion of different Apicomplexa parasites (Adams et al. 1990; Mellouk et al. 1991), it was suggested more recently that NO might itself promote the development of coccidial lesions (Allen 1997a, 1997b).

Cyperus rotundus

possesses diaphoretic and astringent properties and is used to treat disorders of the stomach and irritation of the bowels. It is diuretic, anthelmintic, stomachic and stimulant.

Echinacea purpurea

The anticoccidial effect of *E. purpurea* has been attributed to its immunomodulating properties, which have been widely documented (Stimple et al. 1984; Burger et al. 1997; See et al. 1997; Sun et al. 1999; Currier and Miller 2001; Goel et al. 2002). Ground root preparations of *E.*

purpurea (0.1–0.5%) supplemented to broilers during 2 weeks reduced weight gain retardation and coccidial lesions after a mixed infection at the age of 28 days with *E. acervulina*, *E. maxima*, *E. tenella* and *E. necatrix* (Allen 2003).

Holorrhena antidysenterica (Kutaja)

possesses astringent, antidysenteric, antihelminthic, stomachic, febrifugal and tonic properties, and is used to treat amebic dysentery and diarrhea. It effectively controls ceacal and intestinal forms of coccidiosis in broiler chicks. This drug exhibited coccidiostatic efficacy against all the endogenous stages of *Eimeria tennella* of poultry coccidia.

Tannic acid and gallic acids extracted from the galls of ***Quercus infectoria*** are used in dysentery and diarrhea.

Shankha bhasma

possesses astringent and digestive properties.

Shudda gairika bhasma

Is a silicate of alumina and oxide of iron and aids in absorption of tannins. It helps to balance salts lost due to dehydration.

Tinospora cordifolia

Possesses antispasmodic, anti-inflammatory and antipyretic properties

Zingiber officinale

possesses carminative properties. In veterinary medicine, ginger is used as a stimulant and as a carminative in indigestion of horses and cattle.

Some essential oils extracted from aromatic plants have shown antibacterial properties based on the impairment of the bacterial cell membrane, by changing its permeability to cations, such as H⁺ and K⁺, causing water imbalance and cell death (Lambert R.J., et al. 2001). Because of this mode of action, resistance to phenols is unlikely to develop.

Gentian violet

Also named crystal violet, methyl violet and hexamethyl pararosaniline chloride, is derived from coal tar and known for its antifungal and antibacterial properties. It has been shown to reduce coccidiosis lesion scores in the duodenum and improve weight gain in *Eimeria* spp.

challenged birds. In combination with anticoccidial drugs, it improved feed conversion (Sharkey 1978).

Pediococcus acidilactici

exert antagonism against other microorganisms primarily through the production of lactic acid, in addition to the production of antimicrobial peptides known as pediocins.

More recently, in a study performed with a *Pediococcus*-based commercial probiotic (MitoGrow®) given to birds infected with either *E. acervulina* or *E. tenella*, increased resistance of birds against coccidiosis and a partial protection against growth retardation were demonstrated (Lee et al. 2007a). In another study, performed with a *Pediococcus*- and *Saccharomyces*-based probiotic (MitoMax®), less *E. acervulina* and *E. tenella* oocyst shedding and a better antibody response were found (Lee et al. 2007b).

S. boulardii

has been shown to exert protective effects in *Clostridium difficile* -associated colitis (CDAD) in several animal models. In 10 separate studies in Syrian hamsters, treatment with *S. boulardii* reduced mortality by 51- 80%. This effect is mediated by the release of proteases from *S. boulardii* which digests *C. difficile* toxins A and B. Evidence in support of this mechanism is the observation that anti *S. boulardii* protease antibodies block the protective.

(http://www.wvc.org/images/session_notes_2013/2013_S_27B.pdf)

Enterococcus faecium,
Bifidobacterium animalis,

Lactobacillus salivarius

Lactobacillus reuteri

Lactobacillus acidophilus

Lower intestinal invasion, development of coccidia and oocyst production, explained by enhanced local cell-mediated immunity, were observed with a *Lactobacillus*-based probiotic supplemented diet in *E. acervulina*-infected broilers (Dalloul et al. 2003a, 2003b, 2005).

MOS

In an experiment performed with coccidia, dietary MOS

(1 g/kg feed) were able to reduce the severity of a single

E. tenella infection with 3500 or 5000 sporulated oocysts (Elmusharaf et al. 2006). In another experiment, a dietary

supplementation of MOS at a concentration of 10 g/kg

feed reduced the oocyst excretion and diminished the severity of *E. acervulina* lesions in birds infected orally with a mixture of *E. acervulina*, *E. maxima* and *E. tenella* at subclinical doses of 900, 570 and 170 sporulated oocysts, respectively (Elmusharaf et al. 2007).

Inulin

SALIENT FEATURES OF COXYCARE

- Combination of Natural products
- Specific focus on the intestinal tract immunity development.
- Does not allow the ingested coccidia to penetrate the linings of the intestine
- Does not allow reproduction thus saving the tissue damage.
- Create conditions that the process of release of sporozoites from sporocysts is halted.
- No side effects.
- No resistance.
- No Immunity.
- No reoccurrence.

SUGGESTED LEVEL OF USAGE:

1 Kg/ Ton of feed for 15 days

References:

1. Allen Schoen and Susan Wynn, *Complementary and Alternative Veterinary Medicine*
2. Allen, P.C. and Fetterer R.H. (2002) Recent advances in biology and immunobiology of *Eimeria* species and in diagnosis and control of infection with these coccidian parasites of poultry, *Clinical Microbiology Review*, 15: 58-65.
3. Chaucheyras F. *et al.*, "Effects of a strain of *Saccharomyces cerevisiae* (Levucell SC1) ... on lactate metabolism in vitro" *Can J Microbiol.* 1996. Sep; 42(9): 927-33
4. David McCluggage, *Holistic Care for Birds*
5. Elmusharaf, MA, Peek, HW, Nollet, L and Beynen, AC. 2007. The effect of and in-feed mannaoligosaccharide preparation (MOS) on a coccidiosis infection in broilers. *Anim Feed Sci Technol*, 134: 347–354.
6. Helga Gerlach, Harrison and Harrison *Clinical Avian Medicine and Surgery*
7. Lee, SH, Lillehoj, HS, Dalloul, RA, Park, DW, Hong, YH and Lin, JJ. 2007a. Influence of *Pediococcus*-based probiotic on coccidiosis in broiler chickens. *Poult Sci*, 86: 63–66.
8. Martin SA "Manipulation of ruminal fermentation with organic acids: a review" *J Anim Sci*. 1998 Dec; 76(12): 3123-32.
9. Phyllis A Balch, *Prescription for Herbal Healing*
10. *The Merk Veterinary Manual*
11. Todd-Sanford, *Clinical Diagnosis by Laboratory Methods*
12. Tony Hart and Paul Shears, *Medical Microbiology*
13. Vijayaraghavan G; *A Compendium on Indian Medicinal Herbs*; Studium Press, Houston
14. McFarland, L. V., C. M. Surawicz, et al. (1994). "A randomized placebo-controlled trial of *Saccharomyces boulardii* in combination with standard antibiotics for *Clostridium difficile* disease." *J Amer Med Assoc* 271: 1913-1918.